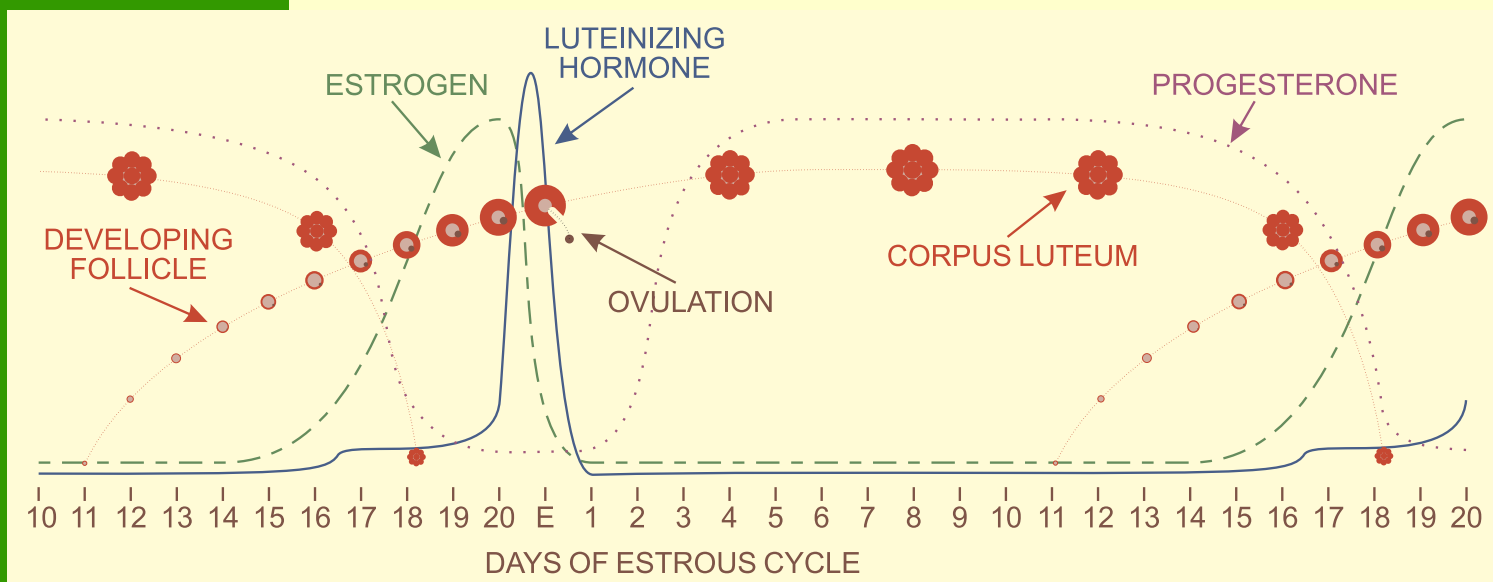


# Cystic Ovaries

A cyst is diagnosed as a large (more than 2.5 cm in diameter), persistent, spherical structure on one of the ovaries. The more common type is the *follicular cyst*, where a developing follicle fails to ovulate and continues to grow. Since no egg is shed, conception is impossible. Follicular cysts can be treated with Gonadotropin Releasing Hormone (GnRH) which stimulates the follicle to ovulate.

Less common is the *luteal cyst*, where the corpus luteum fails to regress at the end of the estrous (heat) cycle. It continues to produce progesterone which blocks development of the follicle which would normally ovulate at the next estrus. Treatment with prostaglandins causes the luteal cyst to regress.



for more information:

[Prevent Cystic Ovaries, Alberta Dairy Management](#)